

# Radiographic Techniques 2

## lecture 6

TMJ view and Useful landmarks of Vertebral Column

By

Ali Hani Kareem

Master of Radiography Techniques /2021

## Temporo-mandibular joints – lateral 25° caudal

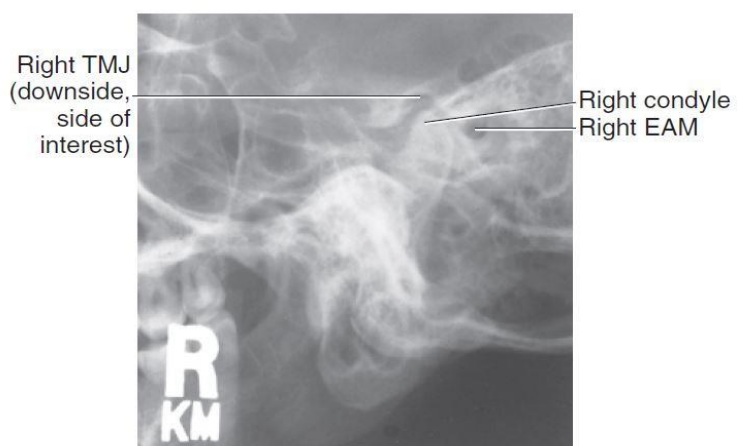
It is usual to examine both TMJs. For each side, a projection is obtained with the mouth open as far as possible and then another projection with the mouth closed.

### Position of patient and image receptor

- The patient **sits facing** the vertical Bucky/skull unit/cassette holder **or lies prone on the Bucky table**. In either case the head is **rotated** to bring the side of the head under examination in contact with the table/Bucky face.
- the median sagittal plane is parallel to the Bucky/receptor and the interpupillary line is perpendicular to the Bucky/ receptor
- The shoulders may be rotated slightly to allow the correct position.
- Two exposures can be made mouth open as possible and then close mouth without superimposition of the images.

### Direction and location of the X-ray beam

- Using a **well-collimated beam**, the **central ray is angled 25° caudally** and will be **centred to a point 5 cm superior to the joint remote from the receptor**. So the central ray passes through the joint



nearest to the receptor.

Figure (1). Temporomandibular joints – lateral 25° caudal

### Useful landmarks of Vertebral Column

1. The mastoid process \_\_\_\_\_ indicates the level of **C1**.
2. protuberance on the posterior aspect of **the inferior part of the neck** \_\_\_\_\_ the spinous process of **C7**
3. **The sternal notch** (also known as suprasternal notch or jugular notch) lies at \_\_\_\_\_ junction between **T2 and T3**.
4. The **inferior angle of the scapula** indicates \_\_\_\_\_ the level of **T7** when the arms are placed by the side.
5. **the sternal angle** indicates **T4**
6. the **xiphisternal joint** is corresponding to **T9**
7. The **lower costal margin** indicates **L3** and is located easily. This is a very useful aid to positioning in spinal radiography.
8. A line joining the **most superior parts of the iliac crests** indicates the level of **L4**.
9. **the tubercle of the iliac crest** discloses the location of **L5**.
10. The **anterior and posterior iliac spines** lie at the level of the **second sacral vertebra**.

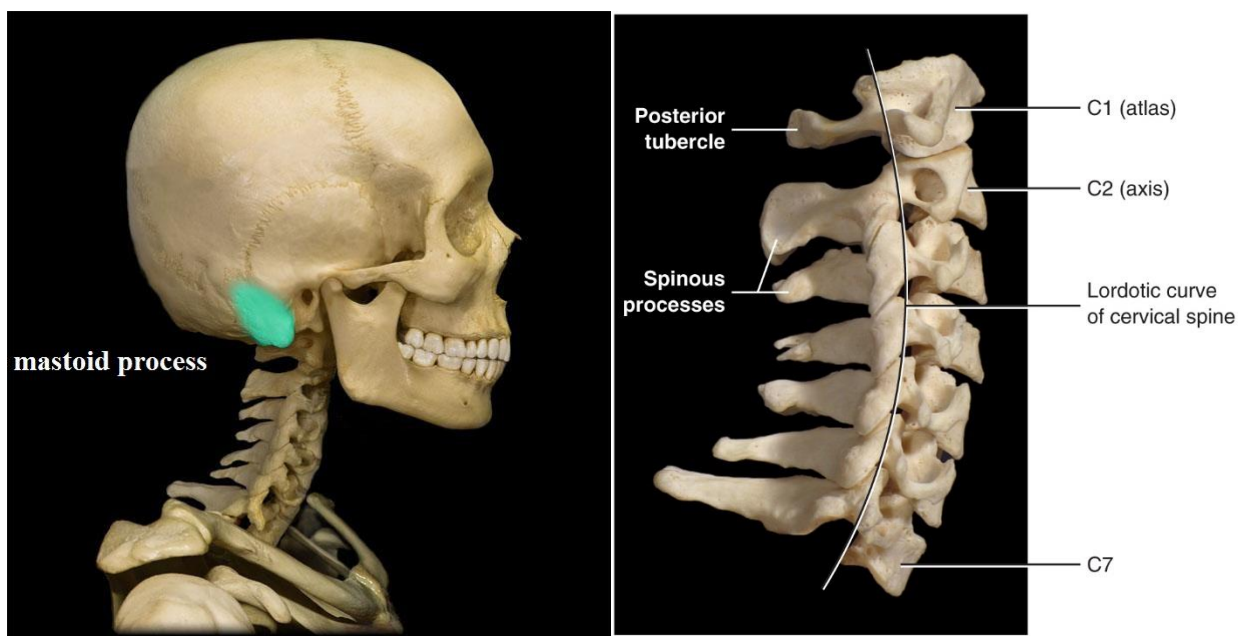


figure (2). Useful landmarks of Vertebral Column

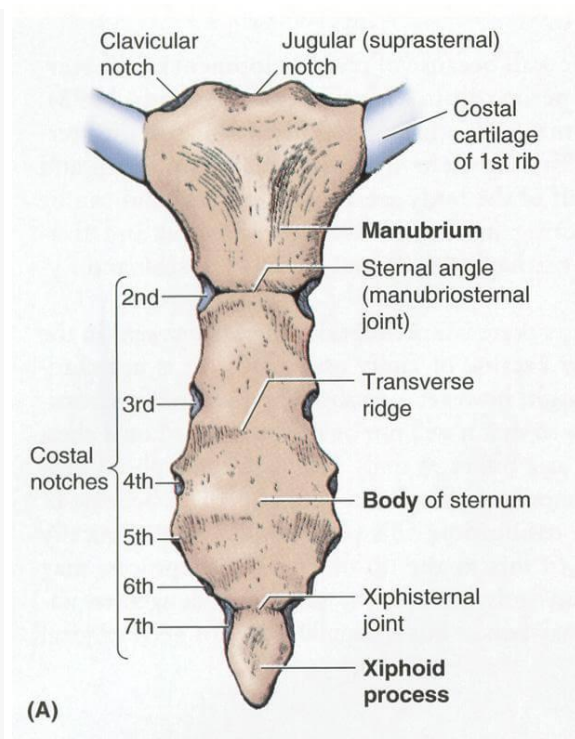
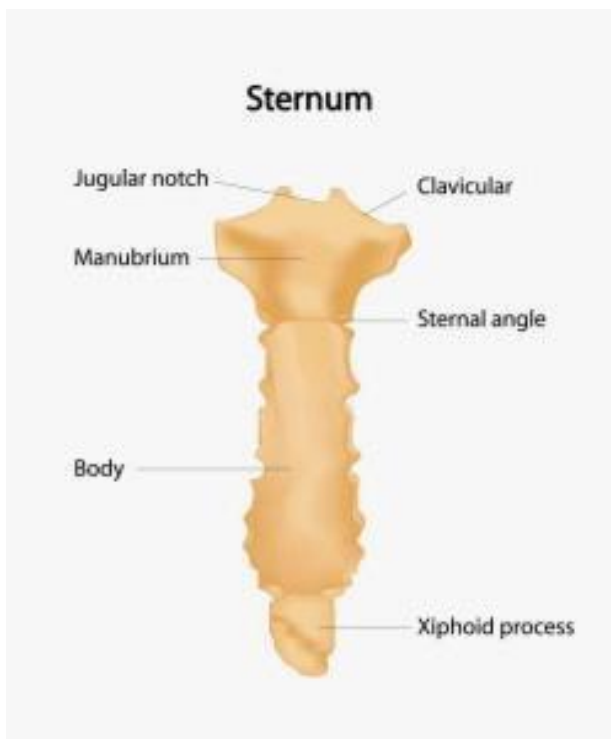
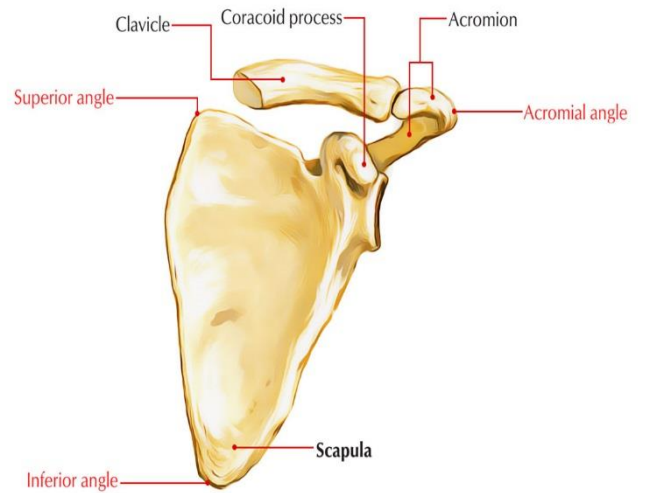
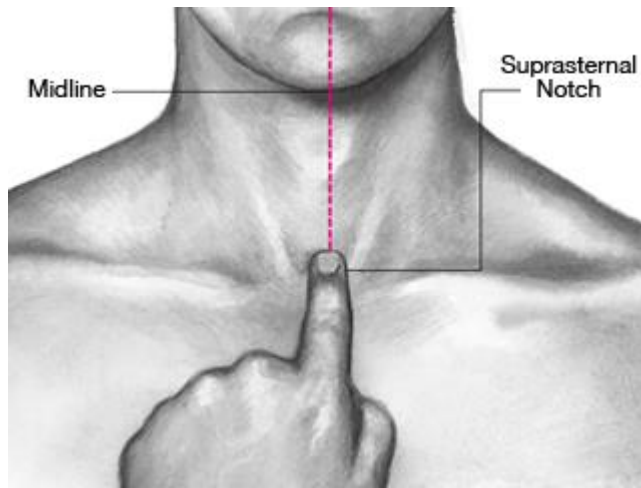


figure (3). Useful landmarks of Vertebral Column

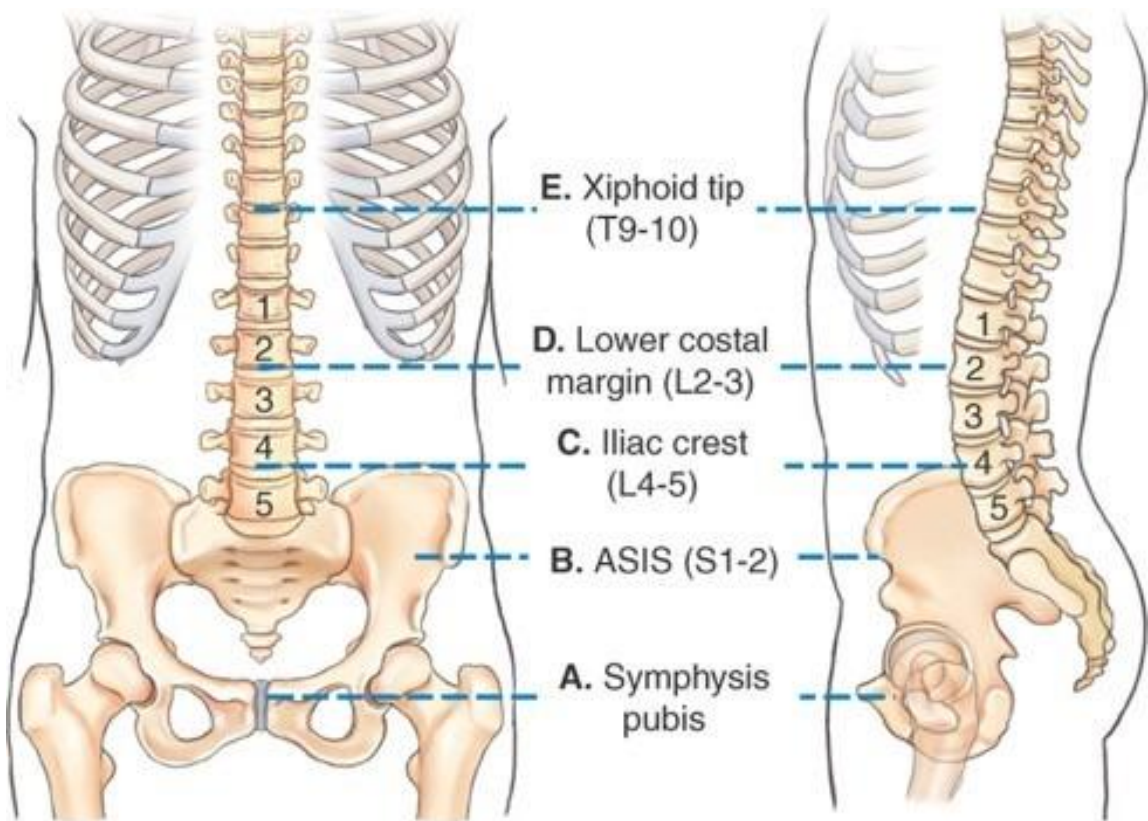
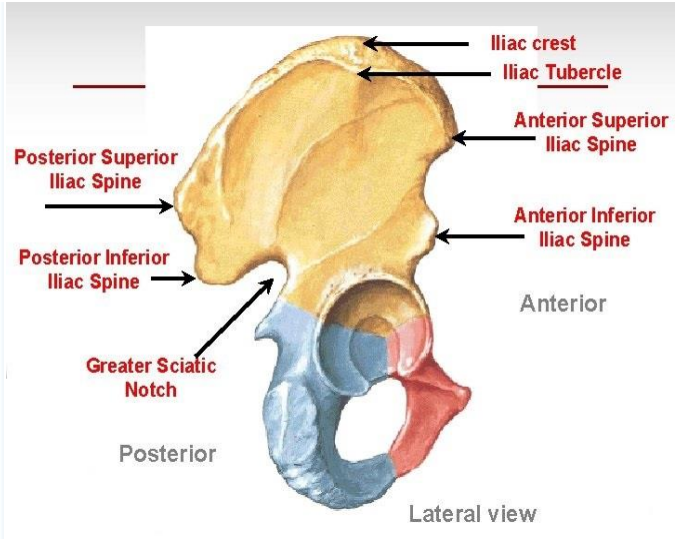
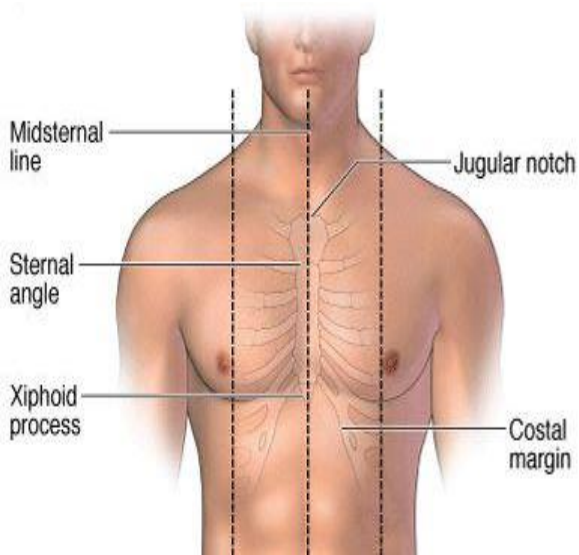


figure (4). Useful landmarks of Vertebral Column

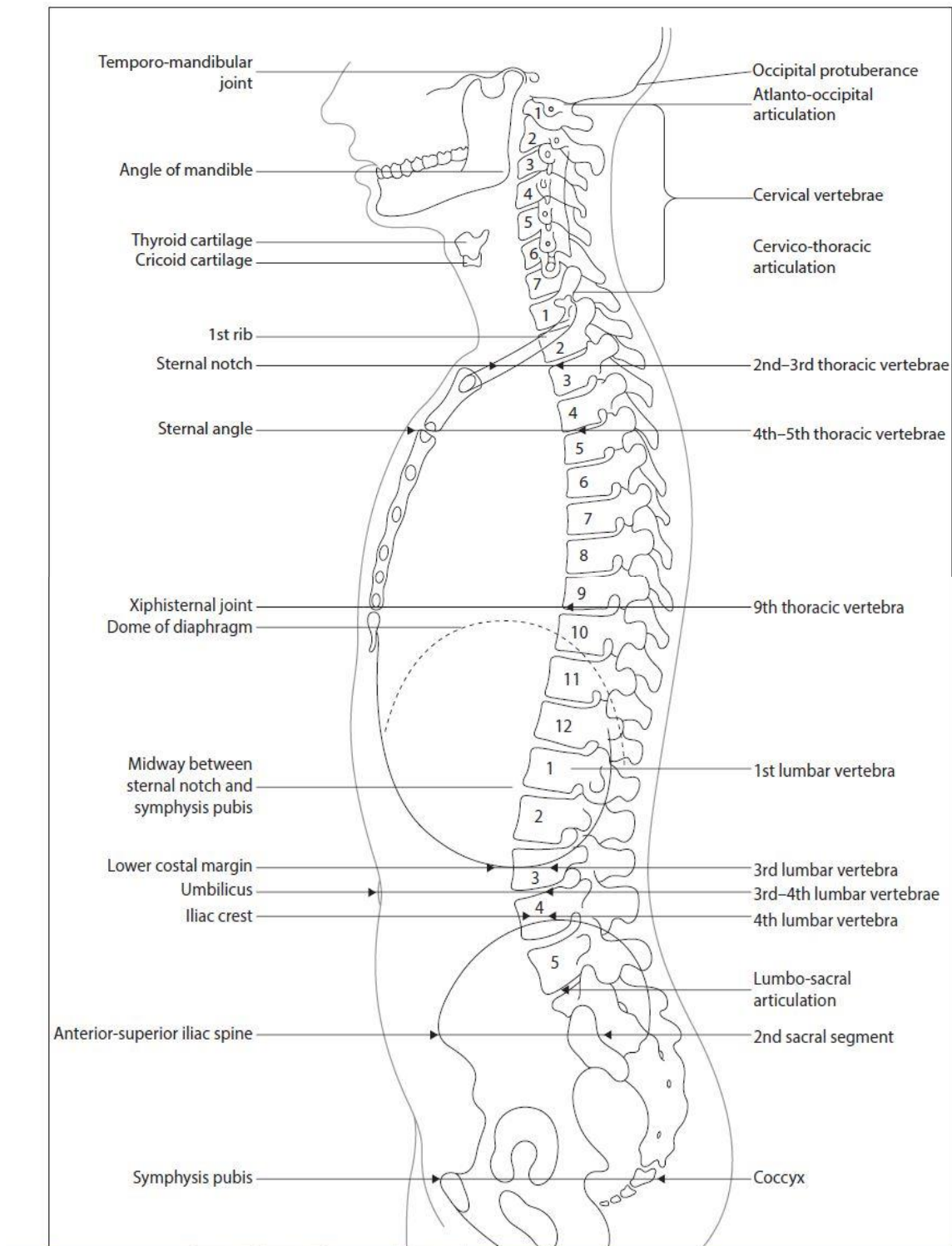


figure (5). Useful landmarks of Vertebral Column